

Suprachoroidal Drug Administration

ASRS 2016
SAN FRANCISCO, CA

Shree Kurup, MD
Claudia Hooten, MD
Michael Stewart, MD
Sara Branson, BS
Allison Toledo, MS

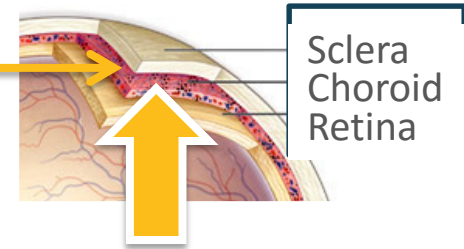
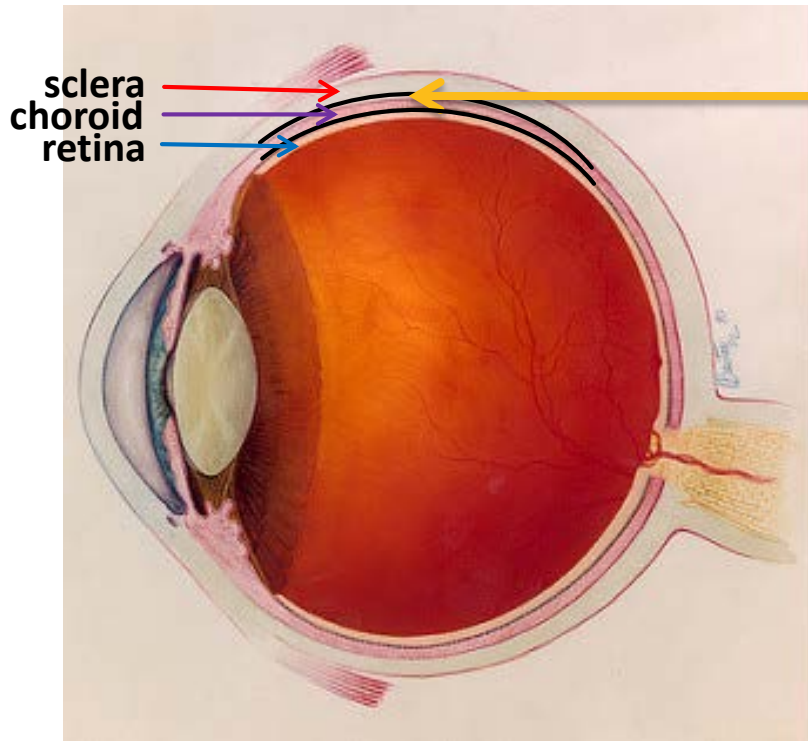
Wake Forest University, NC
University of Kansas, KS
Mayo Clinic, FL

Pertinent disclosures

- Multiple studies through the university
- Advisory Board member

Suprachoroidal Space (SCS)

Potential to treat back-of-the-eye diseases




The suprachoroidal space (SCS)

- Concept of administering drug precisely and specifically may be valuable
- Suprachoroidal administration gives access to posterior tissues

Imaging and histology observations following suprachoroidal administration

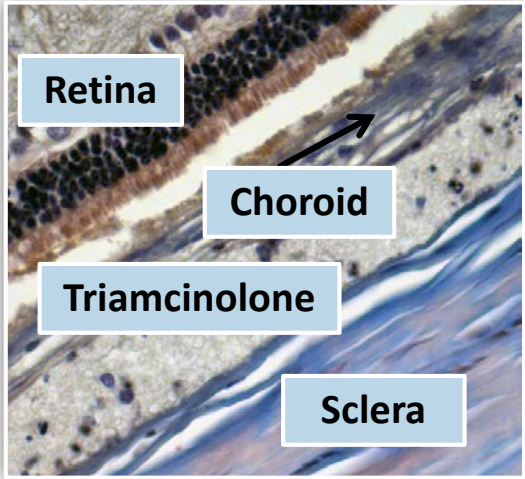
Imaging



Fluorescent particles following suprachoroidal injection in a pig eye

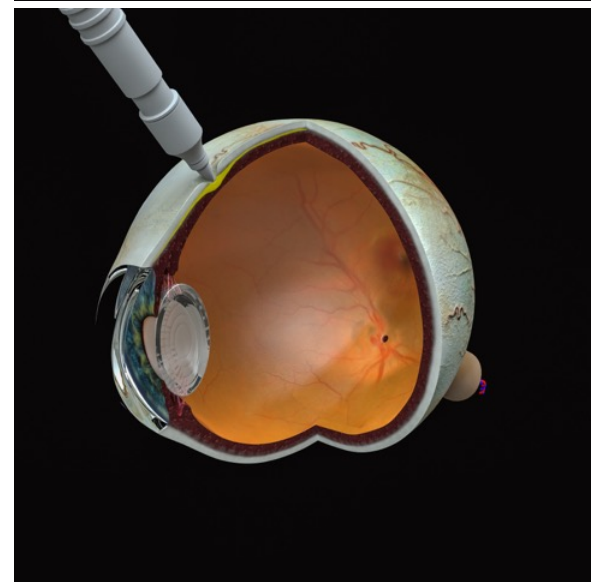
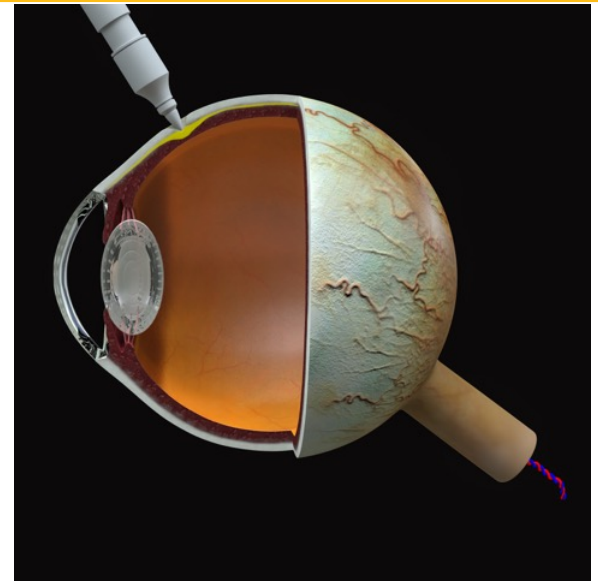
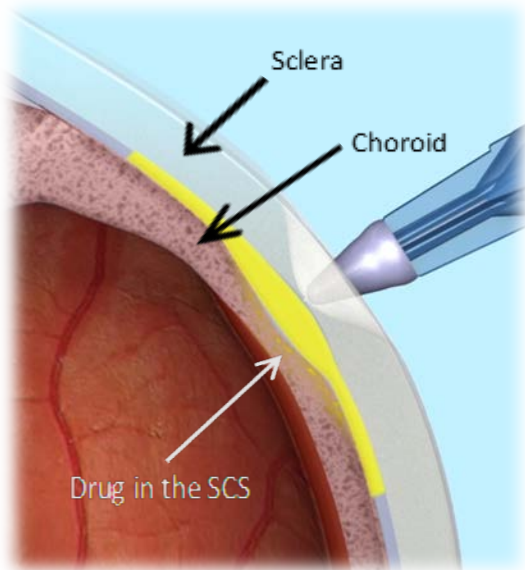
Histology

Triamcinolone acetonide particles following suprachoroidal injection in a rabbit eye

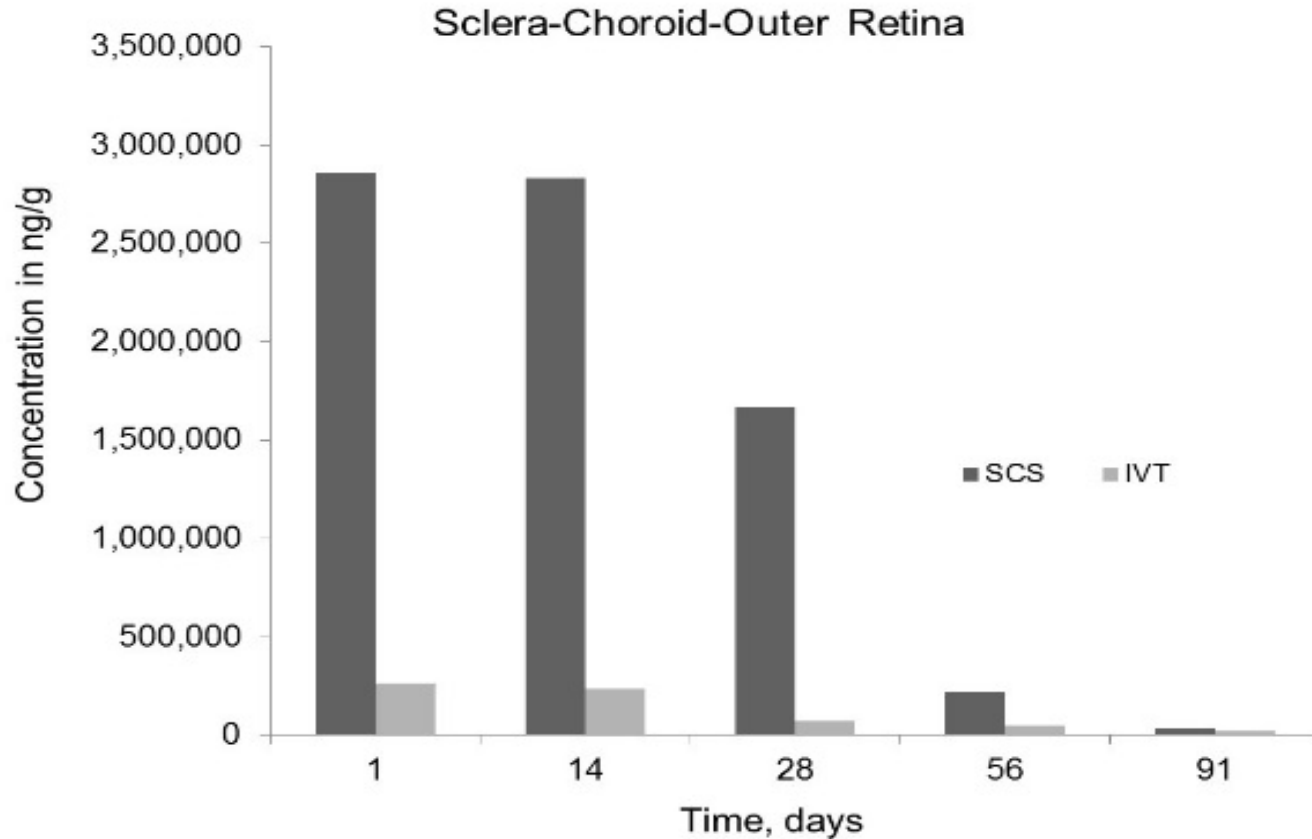


A new drug delivery system for the treatment of uveitis

- Goals:
 - Improved efficacy over current therapies
 - Local administration
 - Less side effects
 - Lower concentration of drug used
 - Less frequent administration of drug



Rabbit Model: High availability of drug in choroid and outer retina through SCS



Dosing through the SCS provides high amounts of drug in the choroid and the retina and much lower amounts in the lens, the iris-ciliary body and the anterior chamber.

Preclinical Studies Summary

- **Pharmacokinetics**

- Unique distribution: drug dominantly in the retina and choroid with low amounts of drug in the anterior segment.
- Potential for lower incidence of IOP increases and cataract formation
- Low systemic levels of drug

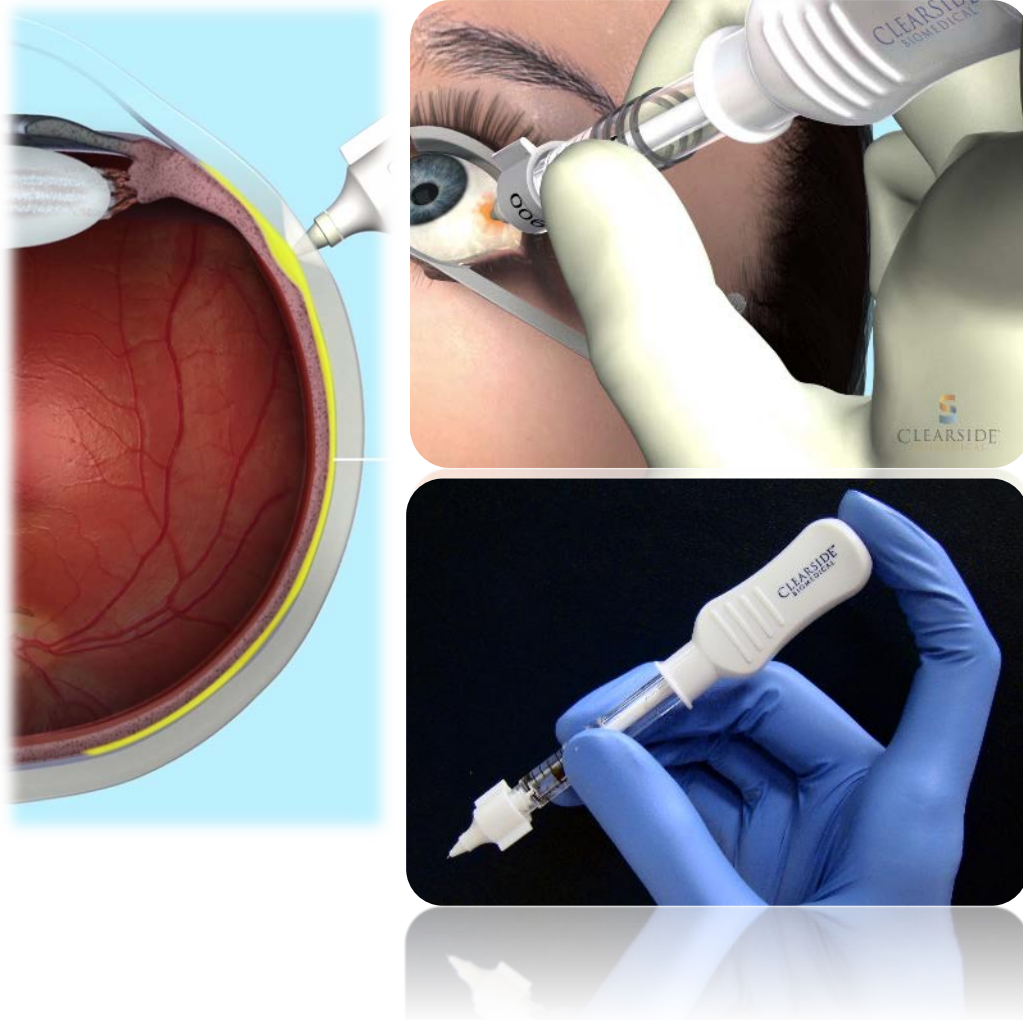
- **Toxicology**

- Toxicology from single and repeat injections with CLS-TA: safe and tolerable

- **Efficacy**

- Lower amounts of drug used compared to intravitreal
- Favorable safety may result from the unique distribution: animal data
- Potential to supplement or replace low doses of oral steroids

Drug Administration



- Approach at **90 degrees** to surface of injection site
- **Insert needle** into conjunctiva
- Establish **“dimple”** around hub
- **Depress plunger handle** gently while maintaining dimple on eye for 3-5 sec
- Feel and observe **plunger movement**

Injection can be completed with **one or two hands**, depending on physician preference

Clinical Studies in Uveitis

- **Phase 1/2**: Open label
 - Safety promising; no IOP increases
 - Efficacy
 - Potential for duration (6 months)
 - **Phase 2**: randomized, masked
 - Met primary end point
 - Statistically significant reduction from baseline in macular edema
 - BCVA changes significant
 - Safety promising; no steroid related IOP increases
 - **Phase 3**
 - Currently enrolling
- **Indication**
 - **macular edema associated with uveitis**
 - Current treatments to improve upon...

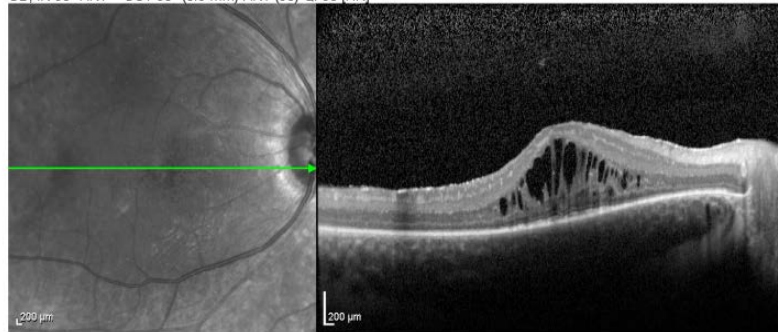
CASE STUDY 1



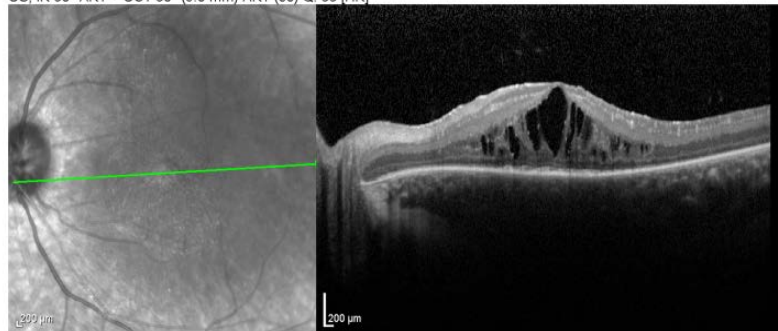
April 20th, 2015 Dex implant OS

- Bilateral uveitis patient with macular edema in both eyes
- Treated with dex implant in the left eye

OD, IR 30° ART + OCT 30° (8.9 mm) ART (98) Q: 30 [HR]



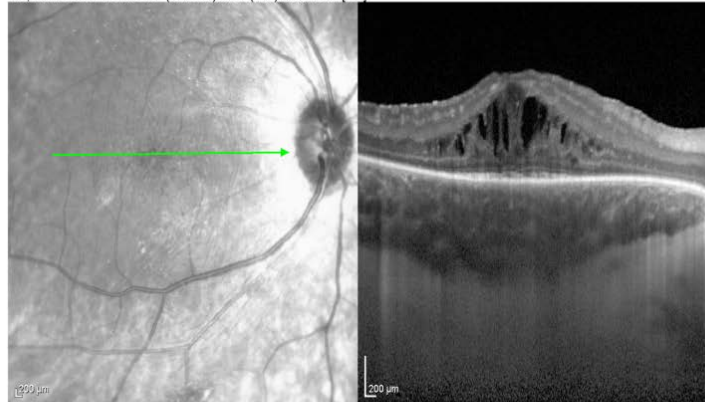
OS, IR 30° ART + OCT 30° (9.0 mm) ART (80) Q: 33 [HR]



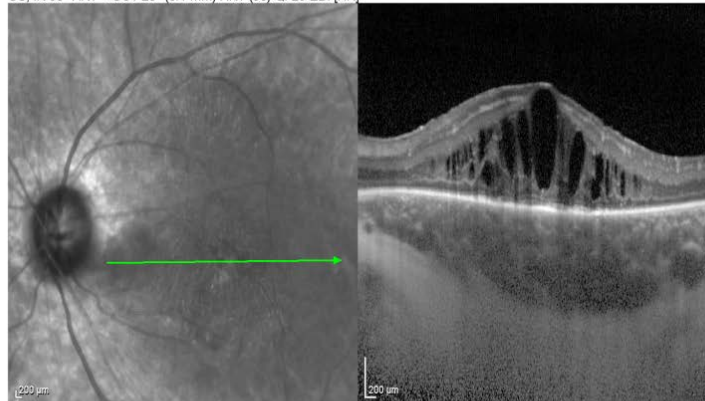
May 7th, 2015 CLS-TA OD

Suprachoroidal CLS-TA right eye in the phase 2 clinical, DOGWOOD, study

OD, IR 30° ART + OCT 20° (6.0 mm) ART (100) Q. 30 EDI [HR]

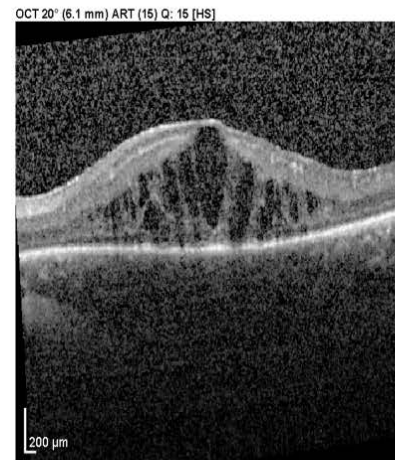
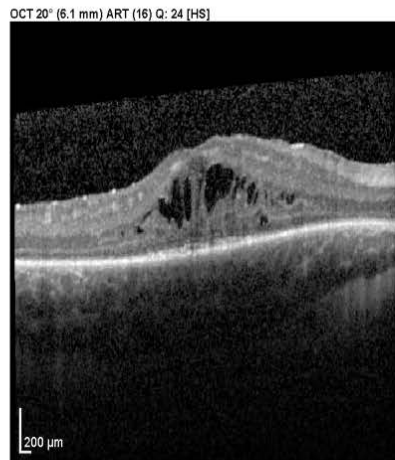
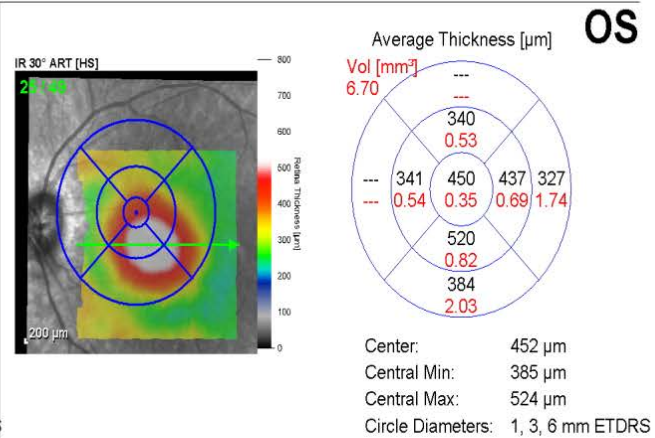
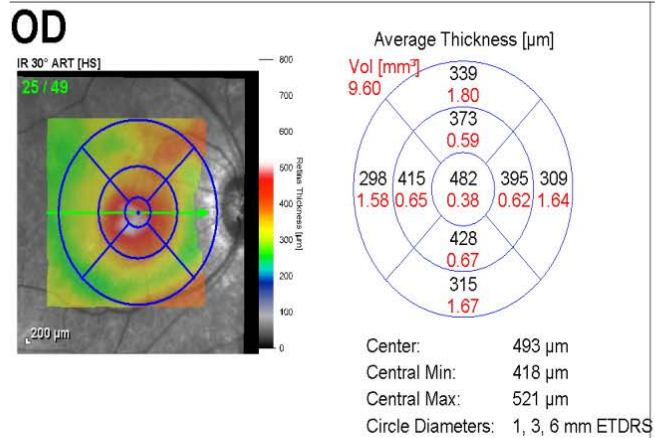


OS, IR 30° ART + OCT 20° (6.1 mm) ART (98) Q. 25 EDI [HR]



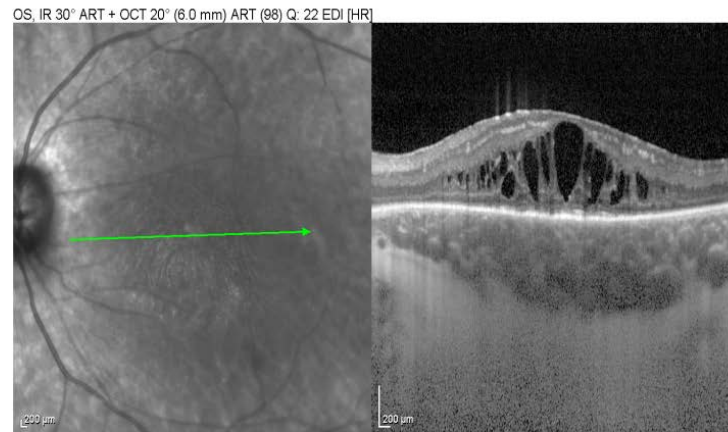
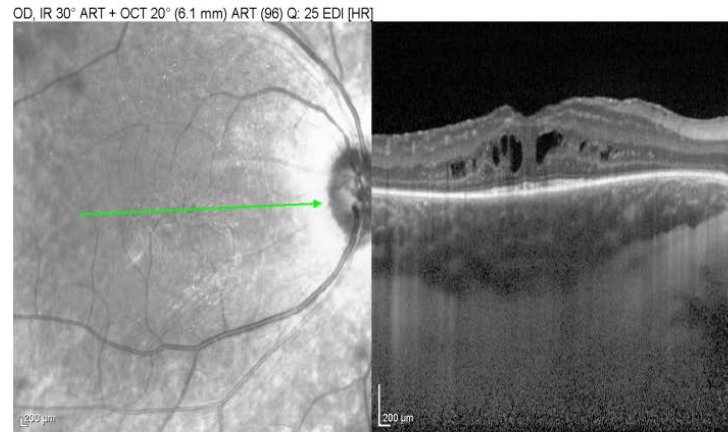
May 14th, 2015; comparison

Note the comparison one week after suprachoroidal CLS-TA; the left eye is 1 month after the dex implant



June 4th, 2015

Note the right eye 1 month after suprachoroidal CLS-TA



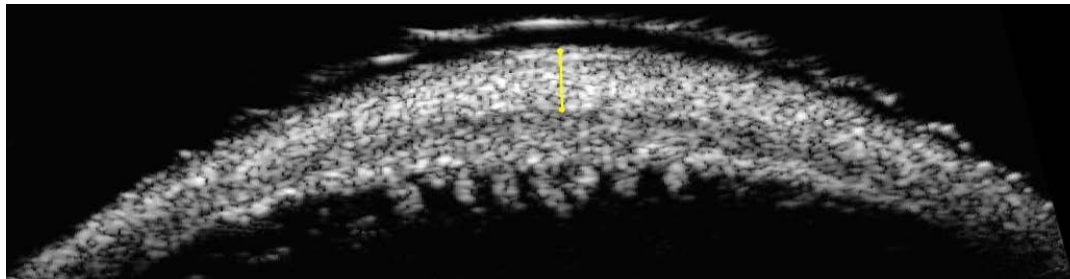
CASE STUDY 2



USG Images : Courtesy Dr Goldstein

**Bilateral uveitis patient with cystoid macular edema in both eyes
Treated with suprachoroidal TA in the phase 1/ 2 trial**

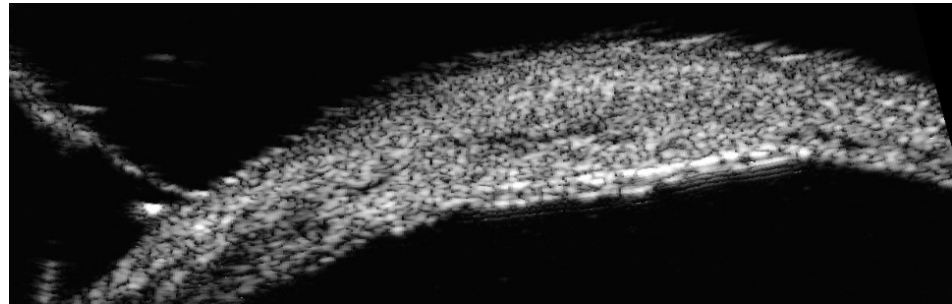
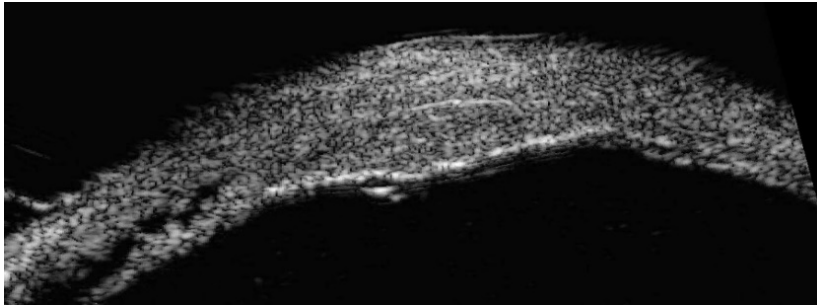
- 4 mm posterior to limbus
- Ultrasound assessment of scleral thickness



● 0.80mm

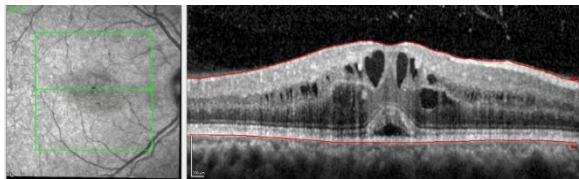
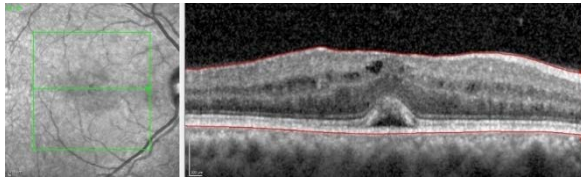
Ultrasound immediately after injection

Ultrasound images immediately after suprachoroidal TA

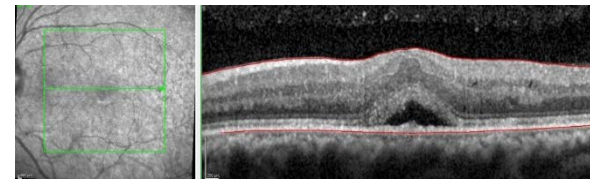
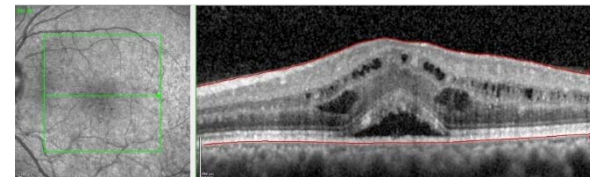


52-year-old woman with bilateral chronic uveitis and CME

**Subtenon TA (STK; 20 mg) in the right eye
Suprachoroidal TA (4 mg) in the left eye**

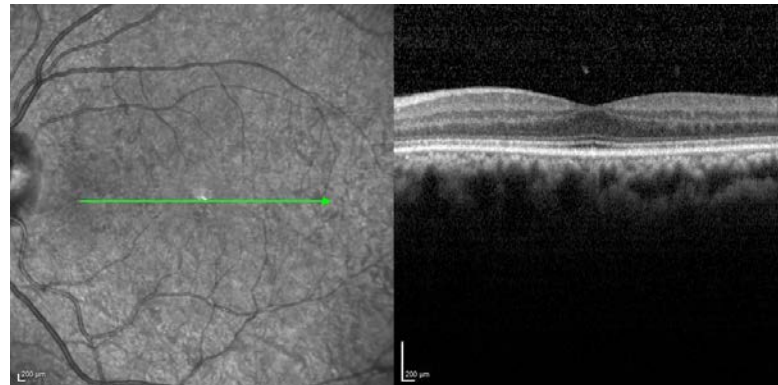
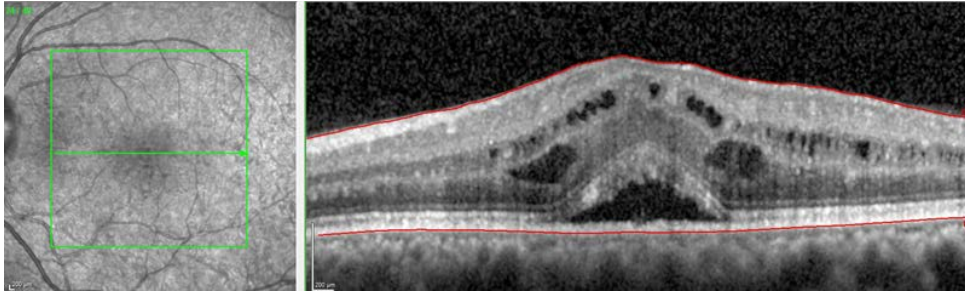


**Over 1 week
STK**



**Over 1 week
Suprachoroidal**

Over 6 months Suprachoroidal



Suprachoroidal space has potential for treating posterior segment diseases

Uveitis

- Phase 1/2: Open label
- Phase 2: randomized, masked
 - Macular edema and visual acuity are improved significantly
 - Safety; no steroid related IOP increases
- Phase 3
 - Currently enrolling

RVO

- Phase 2: randomized, masked, controlled study; met primary endpoint
 - Data to be presented later this year

Clinical data support further development efforts for this new approach to disease treatment

Thank You!

