

Suprachoroidal Administration of Triamcinolone Acetonide

Combined Results of Phase 1/2 and Phase 2 Clinical Studies



Seenu M Hariprasad, MD

Shui-Chin Lee Professor of Ophthalmology and Visual Science

Chief, Vitreoretinal Service

Director of Clinical Research

University of Chicago Department of Ophthalmology and Visual Science

Disclosures

- Consultant or Speaker's Bureau
 - Clearside Biomedical, Ocular Therapeutix, Janssen, Alcon, Allergan, Bayer, OD-OS, Spark, Takeda, Leica, Alimera Sciences, and Regeneron

Commonly treated with corticosteroids and/or immunosuppressive agents

- Macular edema (ME) is the most common cause of vision loss
 - 40% to 60% of intermediate, pan-, and posterior uveitis¹
 - 20% anterior uveitis¹

ME associated with uveitis is treated almost exclusively with local administration of corticosteroid

- Commonly used steroids include dexamethasone, fluocinolone, and triamcinolone acetonide (TA)
- TA has been demonstrated to reduce the complications of uveitis, including ME, and improve visual outcomes^{2,3}

1. Lardenoye CWTA et al. *Ophthalmology*. 2006;113(8):1446
2. Nozik RA. *Trans Am Acad Ophthalmol Otolaryngol*. 1974;76:695
3. Munk MR et al. *Retina*. 2013;33:1673

Mechanisms for Local Administration of Corticosteroids

Challenges exist with all current methods to locally administer steroids

- Incomplete delivery
- Inconsistent delivery
 - Uncertain concentration of TA suspensions in syringe when preparing drug
 - Amount of drug diffusing to retina and choroid is uncertain
- Side effect profile: IOP elevation and cataract formation
 - 35–39% develop a moderate IOP elevation with TA¹
 - 1–5% develop a significant IOP elevation requiring IOP lowering surgery²

Suprachoroidal administration is a novel treatment approach for the eye

- In preclinical animal models, drug administered suprachoroidally had high posterior tissue bioavailability
 - Drug distributes preferentially to the choroid and retina
 - Drug level in the anterior segment is minimal
 - Favorable efficacy is found with as little as 1/10th of intravitreal steroid dose

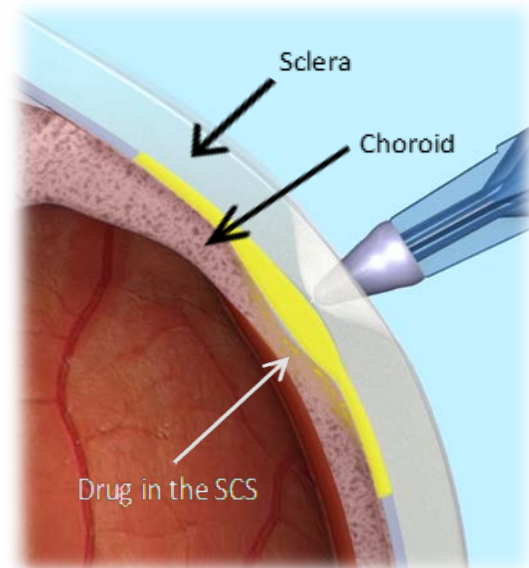
1. Razeghineja MR *et al.* Steroid-induced iatrogenic glaucoma. *Ophthalmic Res.* 2012;47(2):66-80.

2. Becker B. Intraocular pressure response to topical corticosteroids. *Invest Ophthalmol.* 1965;4:198-205.

Suprachoroidal Administration for Treatment of Uveitis

Suprachoroidal injection could become a useful approach for the treatment of ocular conditions affecting the posterior segment of the eye

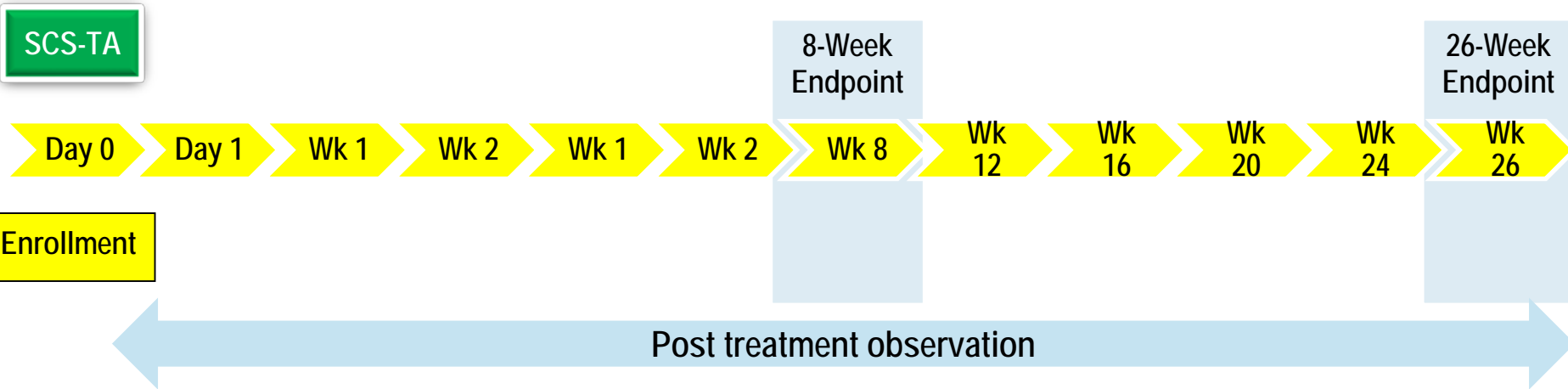
- **Novel technique exists for suprachoroidal injection of drug utilizing a proprietary micro-injector syringe device**
 - 30g needle approximately 1000 μm in length
- **Proposed benefits**
 - Efficacy advantages due to high bioavailability
 - Longer duration of effect
 - Fewer side effects as TA kept away from anterior structures



In Phase 1/2 and Phase 2 trials, consistent efficacy was observed, *with a favorable safety profile*, in patients with ME associated with uveitis

Background: Phase 1/2 Study in Noninfectious Uveitis

Study design



Open label, multi-center study

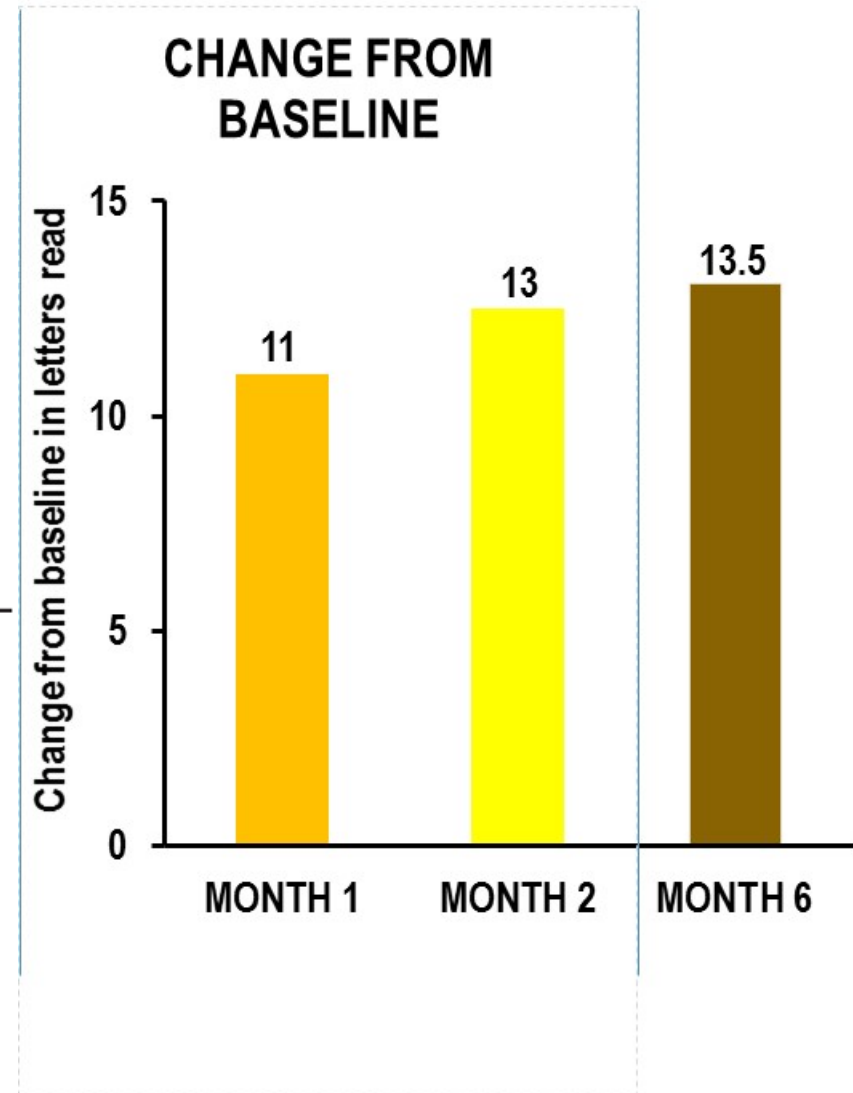
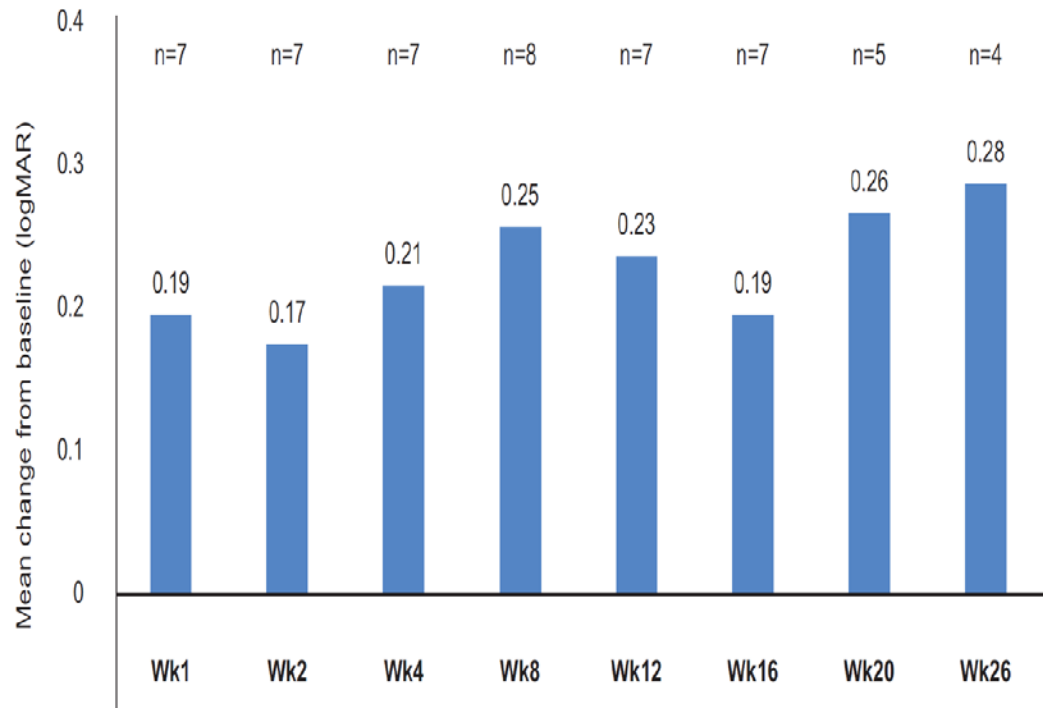
- Subjects with noninfectious uveitis, and
 - Vitreous haze ≥ 1.5 or macular edema $> 310 \mu\text{m}$ on SD-OCT
 - BCVA $+1.0$ logMAR or better (20/200 Snellen equivalent) by ETDRS
- Single suprachoroidal injection of TA
 - Subjects were to be observed for 26 weeks post treatment
 - 8 subjects* received a single unilateral suprachoroidal injection of TA and followed for 26 wks

*of 11 total subjects

Demographics and Disease Characteristics

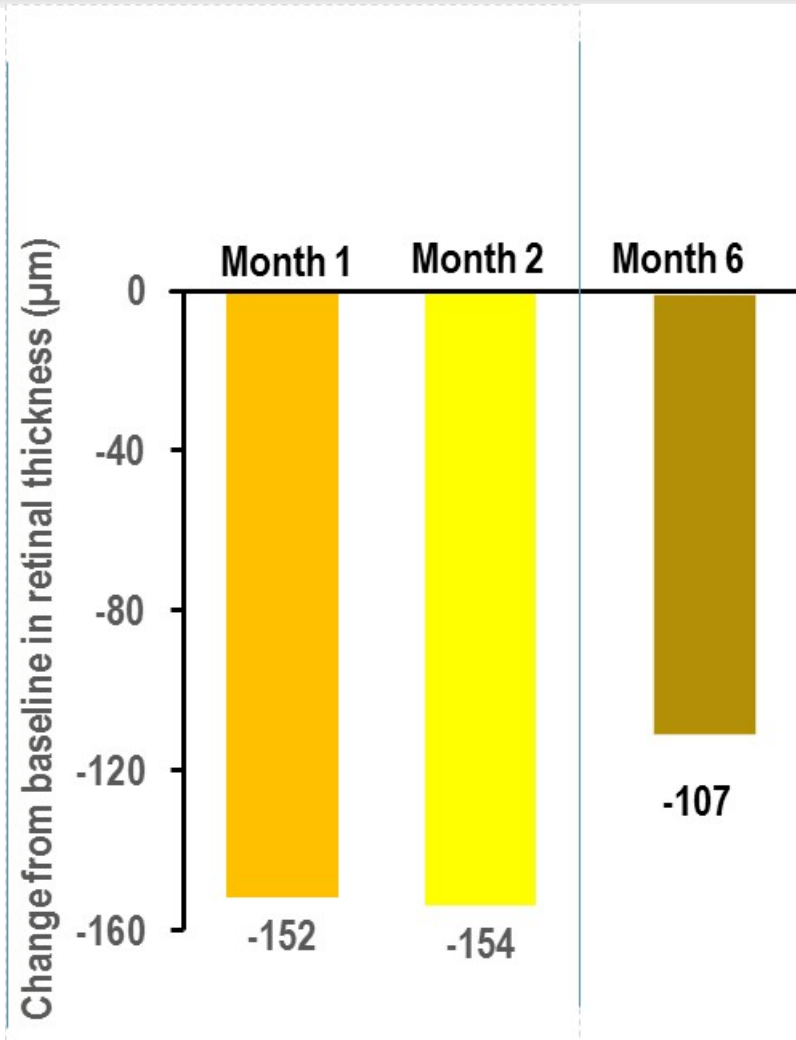
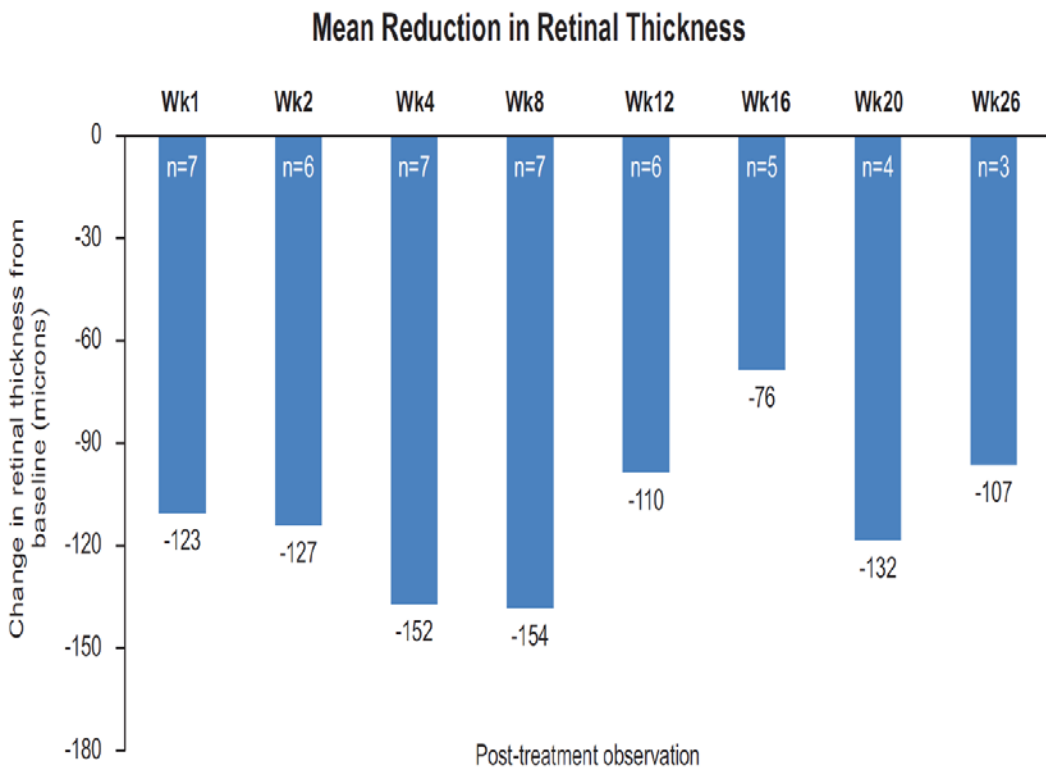
Parameter	N=11
Female, n (%)	8 (73)
Age in years, median (min, max)	60 (42, 78)
Race, n (%)	
African American	6 (55)
Caucasian	4 (36)
Other	1 (9)
Uveitis classification for the study eye	
Anterior plus intermediate uveitis	3 (27)
Intermediate uveitis	2 (18)
Pan-uveitis	6 (55)
Intraocular pressure in mmHg, median (min, max)	14 (10, 19)
BCVA (ETDRS) base logMAR score median (min, max)	0.50 (0.0, 1.0)
Central subfield thickness in microns, median (min, max)	469 (227, 825)

Phase 1/2 Study – Change in Visual Acuity from Baseline



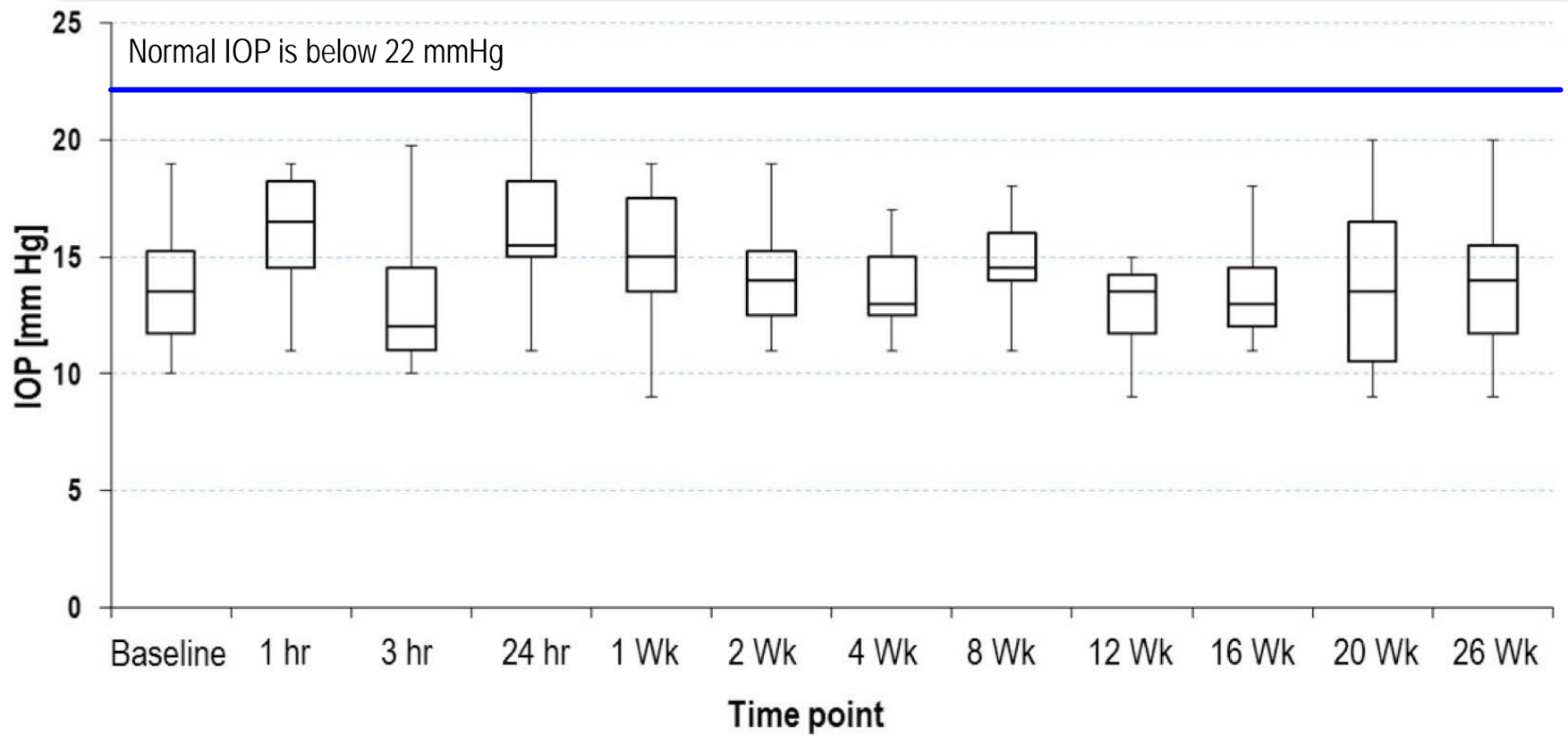
	Week 4	Week 8
Improvement in BCVA	N=7	N=8
	n (%)	n (%)
≥10 letters	5 (71)	6 (75)
≥15 letters	2 (29)	5 (63)

Phase 1/2 Study – Change in Retinal Thickness from Baseline



Reduction in Macular Edema	Week 8 N=7 n (%)
≥20%	4 (57%)

Phase 1/2 Study – Changes in IOP



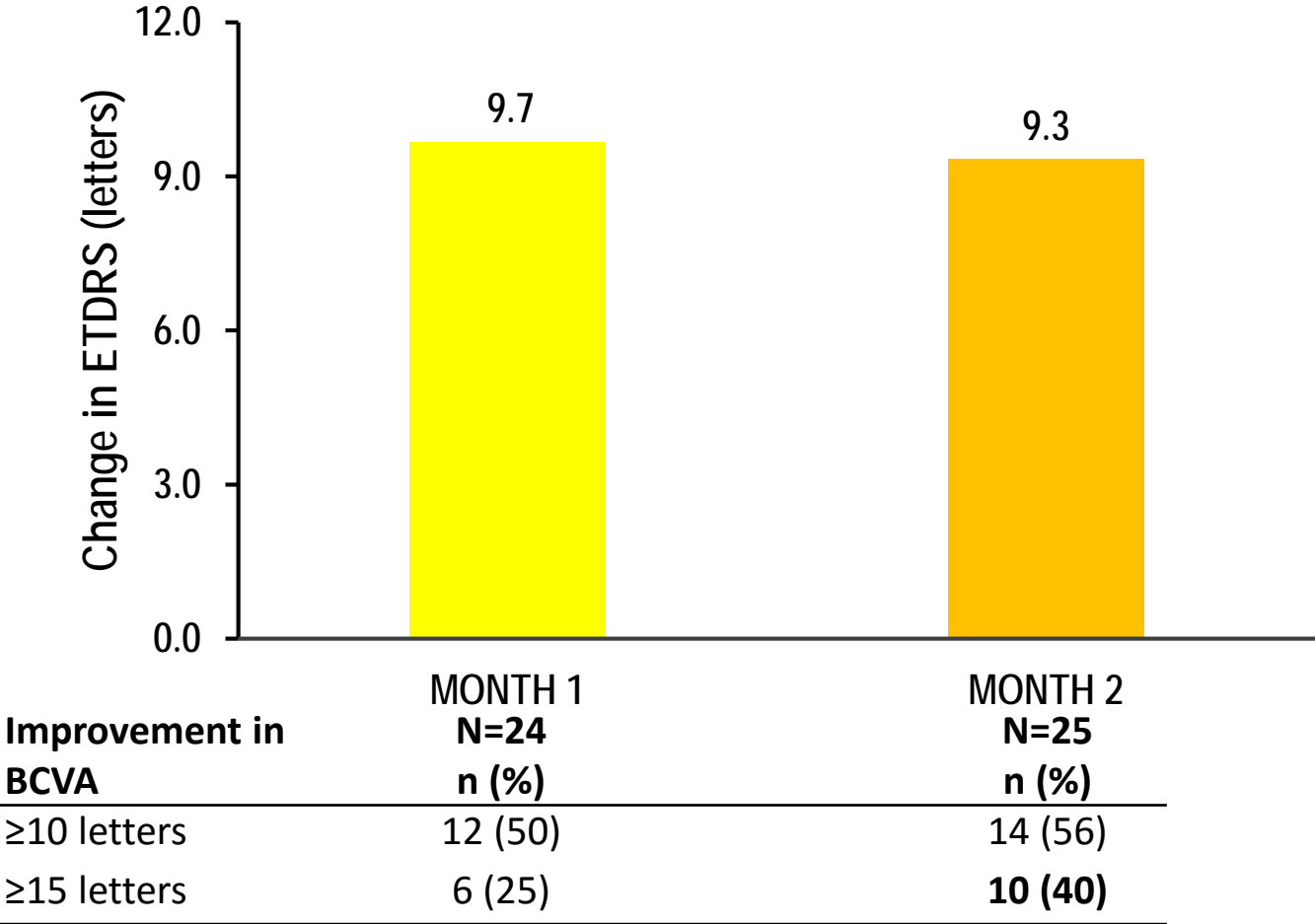
Safety Overview from Phase 1/2 Trial

38 total events

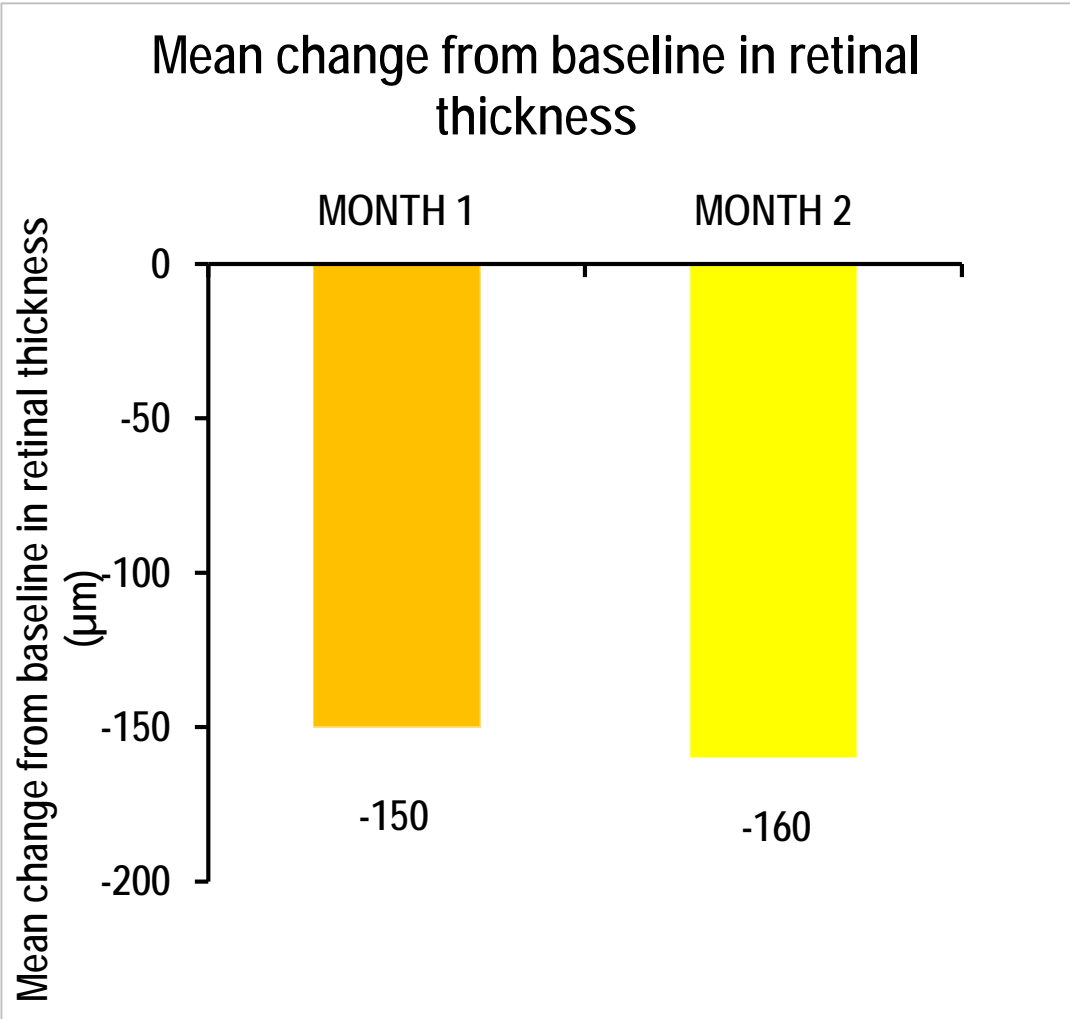
- Most mild to moderate (89%)
- 8 systemic AEs
 - 1 serious systemic AE, pulmonary embolism
 - Patient with known history of pulmonary embolism
 - None related to study treatment
- 21 ocular AEs
 - Most common ocular AE was eye pain which was attributed to procedure
 - 1 serious ocular AE, retina neovascularization
 - Due to progression of underlying disease
 - Not related to study drug

Combined Efficacy from Phase 1/2 and Phase 2

Change in BCVA from Baseline (N=25)



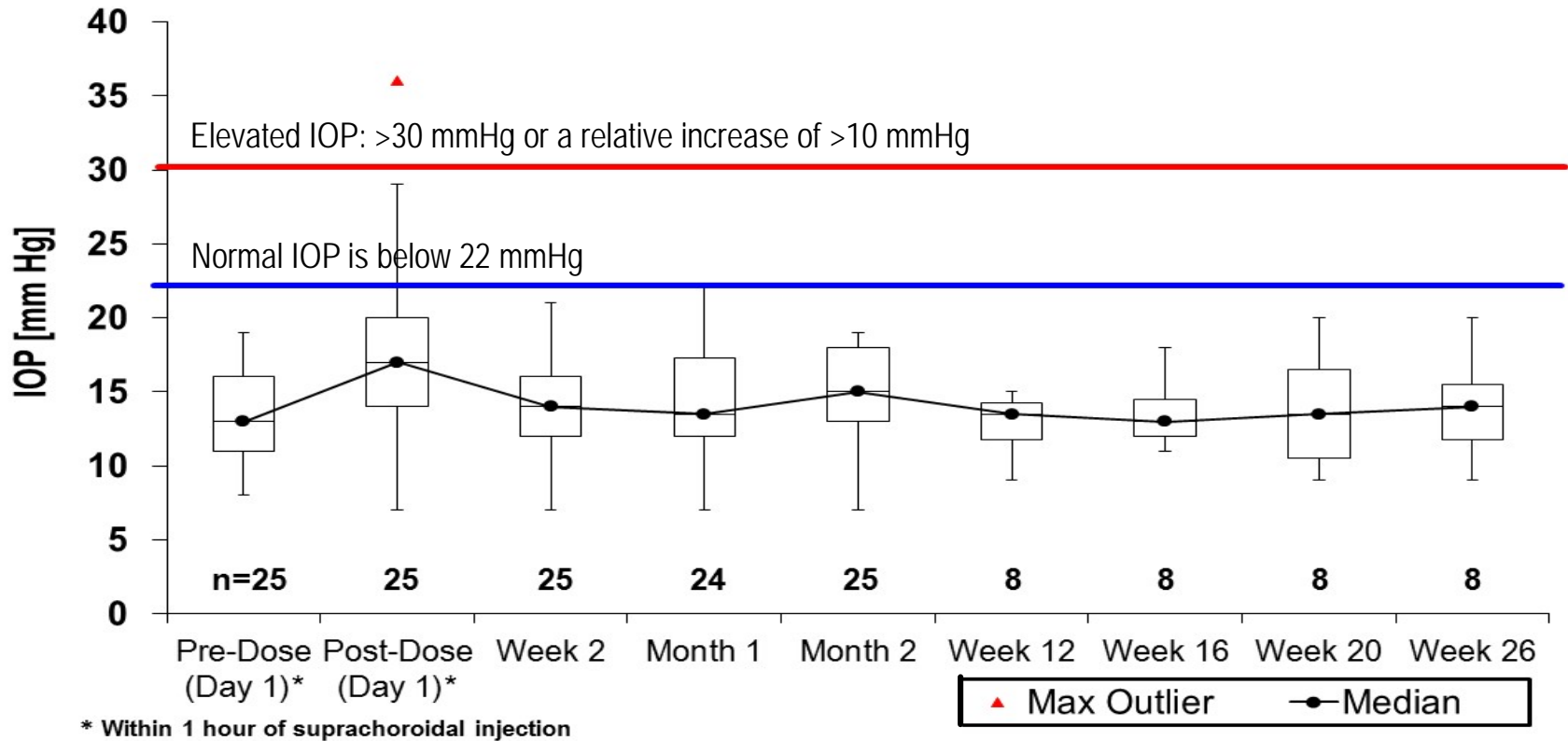
Combined Efficacy from Phase 1/2 and Phase 2



Combined Safety Overview from Phase 1/2 and Phase 2 Trials

- 43 ocular AEs
 - 21 from the Phase 1/2 and 22 from the Phase 2
 - No serious ocular AEs related to study drug
 - Most common ocular AE was eye pain which was attributed to procedure
 - 5 from Phase 1/2 and 4 from Phase 2
 - Two incidents (one in each study) of punctate keratitis
 - Single incidents of conjunctival hemorrhage, conjunctival edema, dry eye, eye irritation, ocular discomfort, eyelid margin crusting, retinal ischemia, and retinal neovascularization
- 2 systemic AEs, both serious
 - Pulmonary embolism and atrial fibrillation, one from each study
 - Neither related to study drug

Combined IOP Changes From Phase 1/2 and Phase 2



- No patient experienced steroid related IOP rise in either clinical trial
- No IOP lowering medication was required in any patient

Key Findings

Study data demonstrated proof of concept that suprachoroidal administration is a new approach with the potential for treating macular edema associated with non-infectious uveitis

- Findings include improvements in visual acuity and reductions in CRT
- Lack of steroid induced IOP rise in these two clinical studies suggests that the ocular distribution of the drug spared the anterior segment

These Phase 1/2 and Phase 2 clinical data support the belief that drug delivery to the suprachoroidal space can be a novel treatment approach for various posterior segment diseases



THE UNIVERSITY OF
CHICAGO



THANK YOU